

MICROENDOSCOPIC DISCECTOMY COMPARED WITH STANDARD MICROSURGICAL DISCECTOMY FOR TREATMENT OF UNCONTAINED OR LARGE CONTAINED DISC HERNIATIONS

Constantin Schizas, F.R.C.S.

Hôpital Orthopédique
de la Suisse Romande, and
University of Lausanne,
Lausanne, Switzerland

Elefterios Tsiridis, F.R.C.S.

Department of Orthopaedics,
Whittington Hospital,
London, England

Joyti Saksena, M.R.C.S.

Department of Orthopaedics,
Whittington Hospital,
London, England

Reprint requests:

Constantin Schizas, F.R.C.S.,
Hôpital Orthopédique
de la Suisse Romande,
Avenue P Decker 4,
1005 Lausanne, Switzerland.
Email: cschizas@hotmail.com

Received, October 8, 2004.

Accepted, April 28, 2005.

OBJECTIVE: Minimally invasive spinal techniques have been developed for years in an attempt to minimize trauma. However, most endoscopic techniques have been unable to address uncontained or large contained disc herniations. The aim of this prospective study was to compare the results of microendoscopic discectomy (MED) and microsurgical discectomy in the treatment of patients with uncontained or large contained disc herniations.

METHODS: An independent observer reviewed the treatment of 28 patients. The study group included 14 consecutive patients who underwent MED and 14 consecutive patients who underwent microsurgical discectomy for radicular pain secondary to uncontained or large contained disc herniations during the same period. Patients were followed up for an average of 12 months. They were assessed by use of Oswestry disability questionnaire and low back pain outcome score.

RESULTS: The average outcome score improvement was of clinical significance in both patient groups. No difference in the scores was found between the two groups. Patients in the MED group required less postoperative analgesia during their stay. One patient in the MED group had a dural tear.

CONCLUSION: MED is at least as effective as microsurgical discectomy for treatment of uncontained or large contained disc herniations, although the advantages over the open technique are short lived and did not reach significance. Nonetheless, for the surgeon accustomed to endoscopic techniques, MED seems to be a safe procedure.

KEY WORDS: Disc herniation, Minimally invasive techniques, Surgery

Neurosurgery 57[ONS Suppl 3]:ONS-357–ONS-360, 2005

DOI: 10.1227/01.NEU.00000176650.71193.F5

Surgical treatment for herniated lumbar discs was first described more than 70 years ago (7). By 1977, refinements in approach led to the development of microsurgical discectomy (MSD) (1). Since then, various minimally invasive techniques have been developed that have been aimed mainly at removing nucleus pulposus at the center of the disc via a posterolateral approach. Those techniques, represented chiefly by automated percutaneous lumbar discectomy, have been unable to address lesions other than contained disc protrusions of moderate size in normally constituted canals. Furthermore, the efficacy of those techniques has not been proven (2).

The “gold standard” in surgical treatment of patients with disc herniations, particularly in the presence of sequestered fragments or associated lateral recess stenosis, is now considered to be MSD (6). In 1997, a new, minimally invasive surgical technique was developed: microendoscopic discectomy (MED) (4). This technique involves use of retractors, intro-

duced percutaneously over muscle dilators, to create a working channel 18 mm in diameter. Video-assisted visualization and illumination is secured through a specially designed METRx-MD endoscopy system (Medtronic Sofamor Danek, Inc., Memphis, TN). The aim of this study was to compare the results and complications of our initial MED experience versus standard MSD.

PATIENTS AND METHODS

Twenty-eight patients were prospectively observed and reviewed by an independent observer. We included the first 14 patients who underwent MED and a series of 14 consecutive patients who underwent MSD during the same period. Although patients were not randomized between the two groups, the surgeon was not aware of the type of procedure that would be available at the time of admission. This was

dependent on the availability of the MED equipment, which was loaned from the manufacturer for a limited period.

All patients had uncontained or large contained lesions. *Figure 1* shows a typical magnetic resonance imaging scan of such a lesion. Patients with smaller contained herniations were treated conservatively irrespective of symptoms and signs. Average duration of symptoms before surgery was 12.1 weeks in the MED group (range, 7–20 wk) versus 12.8 weeks in the MSD group (range, 6–22 wk). The MED group comprised five women and nine men with an average age of 43 years (range, 31–55 yr). The disc herniations were L4–L5 in nine patients and L5–S1 in five patients. The MSD group comprised eight women and six men with an average age of 41.5 years (range, 26–54 yr). The disc herniations were L4–L5 in seven patients and L5–S1 in seven patients.

Patients were followed up for an average of 12 months (range, 11–29 mo) and were assessed with the Oswestry low back pain disability questionnaire (3) and low back pain outcome score (5). Analgesia consumption during the hospital stay was recorded. Statistical analysis was performed with Fisher's exact test.

Surgical technique

MED was performed with the patient under general anesthesia and in prone position on a Montreal-type mattress. Second-generation METRx endoscopic instrumentation was used (9).

Image intensification was used to place an initial K-wire through the fascia, insert subsequent muscle dilators, and control the position of instruments (*Fig. 2*). After insertion of the tubular retractor, flavectomy, laminotomy, nerve root retraction, and discectomy were performed as in the open technique.

MSD was performed with the Caspar microsurgical retractor (Aesculap Co., Tuttlingen, Germany) and an operating microscope. Level identification also was performed by use of image intensification.

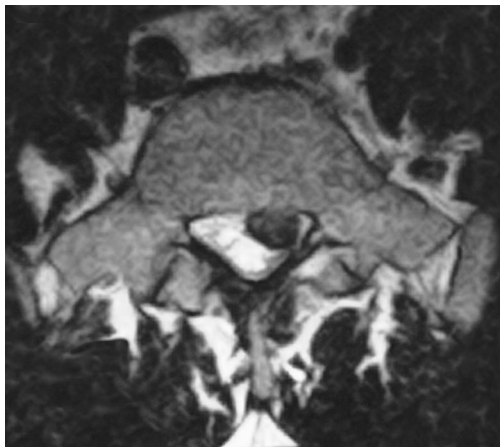


FIGURE 1. Axial T2-weighted magnetic resonance imaging scan of a large contained disc herniation that was treated surgically.

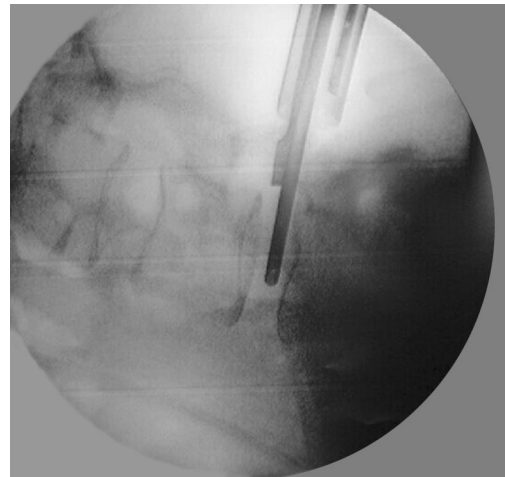


FIGURE 2. Intraoperative fluoroscopy showing tubular retractor, nerve root retractor, and rongeur.

RESULTS

Mean preoperative Oswestry low back pain disability questionnaire score was 65% in the MED group and 64% in the MSD group; postoperatively, mean scores were 22.3% in the MED group and 15% in the MSD group. There was no statistically significant difference in score improvement between the two groups ($P > 0.1$).

Preoperative low back pain outcome scores were 58 points in the MED group and 54 points in the MSD group; postoperatively, values were 17.6 in the MED group and 11.4 in the MSD group. There was no statistically significant difference in score improvement between the two groups ($P > 0.1$).

Patients in the MED group required an average of 8.8 doses of oral analgesia compared with 12 doses for MSD patients. In addition, the postoperative opioid requirement for patients in the MED group was less than that for patients in the MSD group ($P < 0.01$).

Average length of stay was 1.83 days in the MED group versus 2 days in the MSD group. This difference was not statistically significant ($P = 0.5$). One patient in the MED group had a dural tear, which was treated with fibrin glue, whereas another patient developed urinary retention requiring catheterization. Both patients made an uneventful recovery.

DISCUSSION

New minimally invasive techniques are being developed constantly in an attempt to minimize trauma. In spinal surgery, there is concern regarding iatrogenic devascularization and denervation of the paraspinal muscles during the approach (11). This endoscopic technique is attractive in that muscle dissection is minimized. A contrast-enhanced magnetic resonance imaging study demonstrated no significant difference in enhancement of either nerve or muscle tissue

between patients treated with open versus endoscopic technique (8). There has been some initial concern that the two-dimensional view offered by the endoscope might lead to more complications. A system compatible with the operative microscope also has been developed to address those criticisms. Nonetheless, the endoscope allows visualization beyond the confines of the tubular retractor. In addition, during surgery, it is possible to redirect the retractor to provide access to a significant part of the interlaminar space; this offsets the disadvantages of the two-dimensional view.

Another advantage of a smaller working channel is avoidance of excessive nerve root retraction. This has been substantiated by a study of the same technique with intraoperative electromyography (10).

Although our experience was limited to a small number of patients, we determined that it was possible to address uncontained or large contained disc lesions with a minimally invasive technique as effectively as with the classic open technique. We also observed reduced pain medication consumption in patients treated with the endoscopic technique. Nonetheless, this was not a prospective, randomized, concurrently conducted study, and its small size introduces potential for bias and confounding, which may account for any differences found.

MED has advantages over other minimally invasive surgical techniques because it can address lesions otherwise inaccessible to percutaneous techniques with clinical results equivalent to those of standard open microdiscectomy. We acknowledge that the advantages over classic microdiscectomy might be limited, and they do not seem to last longer than the initial postoperative period, as reflected by the equality in outcome scores at 1 year. Nonetheless, we think that for surgeons accustomed to performing endoscopic surgery, use of MED is a safe alternative.

REFERENCES

1. Caspar W: A new surgical procedure for lumbar disc herniation causing less tissue damage through a microsurgical approach, in Wullenweber R, Brock M, Hamer J (eds): *Advances in Neurosurgery*. Berlin, Springer-Verlag, 1977, pp 74–77.
2. Chatterjee S, Foy PM, Findlay GF: Report of a controlled clinical trial comparing automated percutaneous lumbar discectomy and microdiscectomy in the treatment of contained lumbar disc herniation. *Spine* 20:734–738, 1995.
3. Fairbank JC, Couper J, Davies JB, O'Brien JP: The Oswestry low back pain disability questionnaire. *Physiotherapy* 66:271–273, 1980.
4. Foley KT, Smith MM: Microendoscopic discectomy. *Tech Neurosurg* 3:301–307, 1997.
5. Greenough CG, Fraser RD: Assessment of outcome in patients with low-back pain. *Spine* 17:36–41, 1992.
6. Maroon JC: Current concepts in minimally invasive discectomy. *Neurosurgery* 51[Suppl 1]:S137–S145, 2002.
7. Mixter WJ, Barr JS: Rupture of the intervertebral disc with involvement of the spinal canal. *N Engl J Med* 210–215, 1934.
8. Muramatsu K, Hachiya Y, Morita C: Postoperative magnetic resonance imaging of lumbar disc herniation: Comparison of microendoscopic discectomy and Love's method. *Spine* 26:1599–1605, 2001.
9. Perez-Cruet MJ, Foley KT, Isaacs RE, Rice-Wyllie L, Wellington R, Smith MM, Fessler RG: Microendoscopic lumbar discectomy: Technical note. *Neurosurgery* 51[Suppl 1]:S129–S136, 2002.
10. Schick U, Dohnert J, Richter A, König A, Vitzthum HE: Microendoscopic lumbar discectomy versus open surgery: An intraoperative EMG study. *Eur Spine J* 11:20–26, 2002.
11. Sihvonen T, Hernö A, Paljarvi L, Airaksinen O, Partanen J, Tapaninaho A: Local denervation atrophy of paraspinal muscles in postoperative failed back syndrome. *Spine* 18:575–581, 1993.

COMMENTS

Schizas et al. have provided a small but well-designed prospective analysis of microendoscopic discectomy (MED) versus standard microdiscectomy (MSD) for the treatment of uncontained lumbar disc herniation. They have verified the growing nonprospective literature demonstrating results of this new technique at least equivalent to the “gold standard.” Long-term results are at least equal to the results obtained with microscopic technique, and short-term blood loss, pain, and hospital stay are improved. This is the first of the minimally invasive techniques to yield results equivalent to those of the gold standard technique, and in the context of short-term benefits to the patient, this argues strongly for its widespread adoption.

Richard G. Fessler
Chicago, Illinois

Schizas et al. present a review of 28 consecutive patients who underwent a discectomy (MED) via standard microsurgical techniques or via microendoscopic discectomy. With a mean follow-up time of 12 months, Schizas et al. were able to compare short-term and intermediate-term outcomes after discectomies for uncontained and/or large contained lesions. Although this study was not a prospective randomized study, this single-surgeon review demonstrated that the short-term benefits of MED (decreased postoperative pain requirements and statistically insignificant decreased length of hospitalization) did not translate into decreased back pain with the Oswestry Low Back Pain Disability Questionnaire and the Low Back Pain Outcome Score.

Although MED has been demonstrated to decrease length of hospitalization, intraoperative blood loss, and postoperative narcotic use, long-term outcomes have not been properly evaluated. Whether decreased cytokine (C-reactive protein and interleukin-6) expression and decreased electromyographic nerve root irritation translate into improved outcome has yet to be determined. Although magnetic resonance imaging has not differentiated tissue damage between MED and MSD, a muscle dilating/preserving approach has not been demonstrated to preserve the posterior tension band or decrease the amount of postoperative instability. Thus, further investigation is necessary regarding these issues.

Conversely, MED has been demonstrated to be as safe and effective as the traditional MSD. In addition, the benefits mentioned above may justify this minimally invasive approach. Thus, we look forward to further comparisons between these two groups.

Max C. Lee
Daniel H. Kim
Stanford, California

The authors have presented a prospective series of 28 patients undergoing MED versus MSD, the gold standard for uncontained disc herniations. Although their results are not necessarily comparable to those of American surgical practices, in which microscopic discectomy is typically performed as an outpatient procedure, the fact that ultimate outcomes were virtually identical is important. Length of stay was virtually identical; immediate postoperative pain was slightly lower in patients undergoing minimally invasive surgery.

Certainly, from a technical standpoint, there are advantages to minimally invasive microdiscectomy. That may be true philosophically as well. However, it is becoming increasingly difficult to justify the additional costs that minimally invasive surgery offers in many populations.

This small prospective series adds to the voices that question many of the new developments that hold great promise, cost more money, but in the end do not deliver better outcomes for the patients. Frankly, I will continue to perform most disc surgery minimally invasively because of the improved retraction and illumination. However, whether we will be able to do so in the absence of improved outcomes on a long-term basis remains to be determined.

Dennis J. Maiman
Milwaukee, Wisconsin

This study seems to support a broadly held view regarding MED. Specifically, in appropriately trained and experienced hands, MED produces long-term outcomes similar to those with MSD in terms of pain and functional status in patients with symptomatic unilateral lumbar disc herniation. The primary, albeit temporary, benefit of MED over MSD consisted of reduced postoperative pain, indirectly quantified by a 26% reduction in postoperative analgesic intake.

The authors have provided a scientific approach to this important question. Although the promise of reduced postoperative pain with MED has long been assumed, this is among the first studies to critically assess this assumption in a valid manner. Although the study is small and nonrandomized, it is prospective, contains homogeneous patient populations, and uses standardized outcomes assessment.

Interestingly, the MSD patients had an approximately 10% greater improvement than the MED patients on both the standardized Oswestry Disability Index and the Low Back Outcome Score. It is not clear whether this non-statistically significant difference was a result of the

small study size (i.e., β error). A larger prospective and randomized study will be needed to answer this question.

Paul C. McCormick
New York, New York

This article is a well-controlled look at the comparison of MED with MSD. The sample is very small, and the surgeon group is a well-contained group of excellent surgeons. In the hands of these surgeons, the procedure is of equal effectiveness and safety. Unfortunately, not every spinal surgeon has the expertise in MED to achieve these excellent results. Posterior lumbar endoscopic surgery uses the same retractor as MSD and essentially the same techniques that all microscopic surgeons use to remove an extruded posterior lumbar fragment of intervertebral disc and/or to perform a medial facetectomy. The difference with MED is the spatial orientation of the surgeon attempting to manipulate structures in the spinal canal while looking at the monitor and the actual optics involved with the endoscope, i.e., clarity and lighting.

The article expressed the caveat that "A surgeon experienced in endoscopic surgery can achieve these results," and I agree with that conclusion. The problem is with finding an excellent spinal surgeon with excellent endoscopic skills.

Use of the microscope through the tubular retractors is an excellent technique. The skin incision is the same. The hospital stay, the morbidity, and the ultimate outcome should be the same. The risks or benefits to the patient and to the spinal surgeon may be too steep to make MED a popular procedure.

Robert G. Watkins
Orthopedic Spinal Surgeon
Los Angeles, California

